

## Relevance of Stones in Gall Bladder Histology

Neha Garg<sup>1</sup>, Chetan Jain<sup>2</sup>, Sheetal G. Gole<sup>3</sup>, N.C. Mahajan<sup>4</sup>

<sup>1,2</sup>Assistance Professor, <sup>3,4</sup>Professor, Department of Pathology, Rural Tertiary Health Care Center, Haryana, India.

### Corresponding Author:

**Chetan Jain**, Assistance Professor,  
Department of Pathology, Rural Tertiary  
Health Care Center, Haryana, India.

E-mail: [drchetanjain162@gmail.com](mailto:drchetanjain162@gmail.com)

Received on 22.04.2019,

Accepted on 20.05.2019

### Abstract

**Objective:** The most widely accepted hypothesis is bile stasis caused by gall bladder dyskinesia. The aim of this study is to investigate about relationship between gall stones and different gall bladder pathologies. **Methods:** Specimens for study was sent by surgery department for histopathology after cholecystectomy. After grossing, sections were submitted for tissue processing. **Results:** Grossly, size of gall bladder was normal in 91 (60.66%) but fibrotic in 15 (10%) and enlarged in 44 (29.34%) patients. Wall thickness was normal (<3 mm) in 79 (52.67%) and thickened (>3 mm) in 71 patients (47.33%). In microscopy 110 (73.34%) were of chronic cholecystitis, cholesterolosis 15 (10%) cases, xathogranulomatous and acute on chronic cholecystitis 3 cases (2%) each, 1 case (0.67%) each of mucocele and follicular cholecystitis. Hyperplasia was observed in 8 (5.33%) cases. Hyperplasia subclassified into adenomatous and adenomyomatous. Five (3.33%) cases of cholecystitis with metaplasia were seen. There were 4 cases (2.66%) of carcinoma, predominant histologic type being adenocarcinoma. **Conclusion:** Presence of stones may lead to different mucosal changes from chronic inflammation to carcinoma. Therefore histopathological examination of all cholecystectomy specimens with or without cholelithiasis is essential to diagnose benign as well as malignant pathology.

**Keywords:** Cholecystitis; Dysplasia; Hyperplasia and Metaplasia.

### How to cite this article:

Neha Garg, Chetan Jain, Sheetal G. Gole *et al.* Relevance of Stones in Gall Bladder Histology. Indian J Pathol Res Pract. 2019;8(4):459-464.

### Introduction

Gall bladder disease is an emerging problem worldwide [1]. Its fairly common in northwestern India due to increase in sedentary lifestyle and cholesterol rich diet. It is commonly believed

that bile stasis is the prime factor for gallstone formation. The function of the gallbladder is to store bile and to concentrate it during the inter-digestive phase [2]. Gallbladder and biliary tract epithelium excrete high concentrations of potentially harmful compounds [3].

Columnar epithelial cells in gastro-intestinal tract are protected by mucus, which acts like a barrier between the gall bladder mucosal cells and exogenous chemical compounds [4]. The gallbladder mucus mediates formation of stones; therefore it regulates cholelithiasis [5].

Gallbladder dyskinesia is considered as major cause of stasis, which in turn causes gall bladder wall pathology [6]. In earlier stage of gallstone formation, tension of gall bladder is increased rather than decreasing [7]. Stones may lead to different mucosal changes in gall bladder, that is acute inflammation, chronic inflammation, glandular hyperplasia, granulomatous inflammation, cholesterosis, dysplasia, and carcinoma [8].

The aim of this study is to investigate about relationship between gall stones and different gall bladder pathologies.

### Materials and Methods

Prospective study was carried out on 150 patients with gallbladder disease, during two-years period from October 2016 to October 2018. In our study both sexes and all age groups were included. Study population or patients were from North-western India.

Ten percent formalin was routinely used for fixation and submitted to the Pathology Department of Rural tertiary health care center, Haryana.

While gross examination of gall bladder different parameters like dimensions of specimen, wall thickness, type and number of stones were noted. Sections from different anatomical parts (neck, body and fundus) of gall bladder were submitted. Simultaneously sections were also taken from abnormal appearing areas.

Tissue processing and staining by hematoxylin and eosin stain was done according to standard procedures. Findings were recorded under following microscopic categories, hyperplasia, antral metaplasia, intestinal metaplasia, dysplasia and carcinoma in situ and carcinoma.

The following microscopic diagnostic criteria were used:

- *Hyperplasia:* Gall bladder epithelium show pseudostratification of nucleus with overcrowding and scanty mitotic figures.
- *Dysplasia:* Architectural distortion of glands, accompanied by pseudostratification and crowding of nucleus, with loss of polarization and hyperchromasia.

- *Intestinal metaplasia:* Globet cell change in glandular lining.
- *Antral metaplasia:* Presence of gastric antral glands in lamina propria.
- *Carcinoma in situ and invasive carcinoma:* Vesicular or hyperchromatic nuclei with high N:C ratio, scanty eosinophilic cytoplasm, frequent mitosis along with atypical mitosis and architectural distortion of glands with loss of polarity. In invasive carcinoma stromal invasion is present [9].

### Observations

Out of 150 gallbladder specimens, 128 (85.34%) were female and 22 (14.66%) from male patients (M: F ratio 1:5.8). Mean age was 44.3 years (range 8-86). Youngest being 8 year old male and oldest patient was 86 year old female. Single stone was found in 20 gallbladders (14.5%) and multiple stones in 120 (85.5%) (Table 1).

#### Gross features

Size of gall bladder was normal in 91 (60.66%) but fibrotic in 15 (10%) and enlarged in 44 (29.34%) patients. Wall thickness was normal (<3 mm) in 79 (52.67%) and thickened (>3 mm) in 71 patients (47.33%). (Table 2).

The number and nature of stones did not have any bearing on the gross changes.

**Table 1:** Distribution of 150 Cases of Cholecystectomy According to their Age and Gender

Age Group	Male	Percentage (%)	Female	Percentage (%)
<20	1	4.54%	3	2.34%
20-29	3	13.63%	13	10.15%
30-39	2	9.09%	30	23.43%
40-49	7	31.81%	36	28.12%
50-59	4	18.18%	23	17.96%
60-69	5	22.72%	16	12.53%
>70	0	0%	7	5.47%
	22	14.66%	128	85.34%

**Table 2:** Cholecystectomy Specimen on Gross Examination

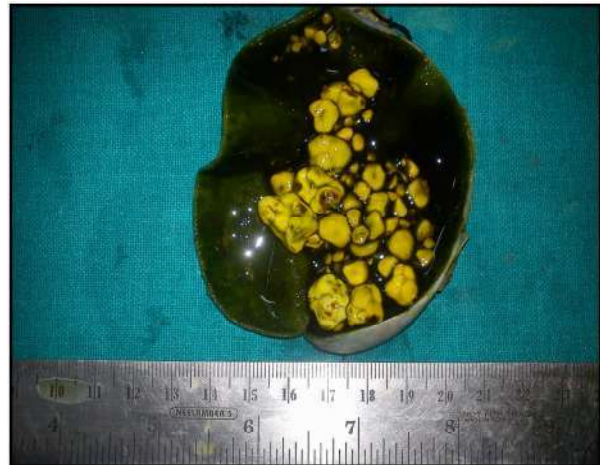Gall Bladder Size			Wall Thickness	
Fibrotic (%)	Normal (%)	Enlarged (%)	<3 mm (%)	≥3 Mm (%)
15 (10%)	91(60.66%)	44(29.34%)	79(52.67%)	71(47.33%)

*Microscopic examination*

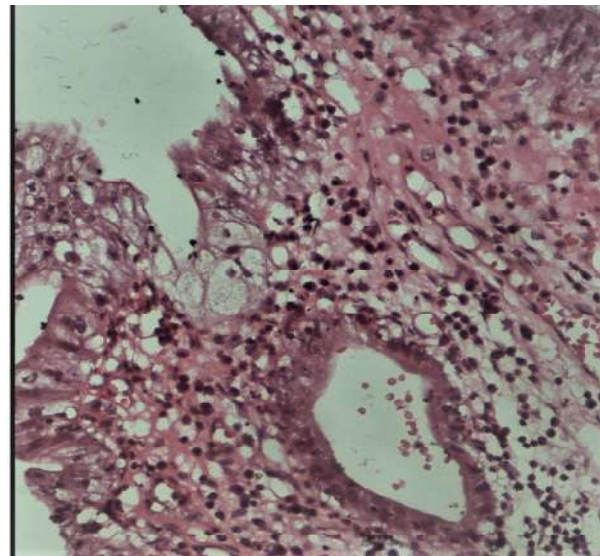
Few cases had more than one mucosal pathology, in those cases prognostically important changes were noted (one condition per case). Most of the cases, 110 (73.34%) were of chronic cholecystitis, cholesterolosis were found in 15 (10%) cases, xanthogranulomatous and acute on chronic cholecystitis were noted in 3 cases (2%) each, while there was only 1 case (0.67%) each of mucocele and follicular cholecystitis. Number of cases of both types of hyperplasia were 8 (5.33%). Five (3.33%) cases of cholecystitis with metaplasia were seen. There were 4 cases (2.66%) of carcinoma, predominant histologic type being adenocarcinoma which is shown in Table 3.

**Table 3:** Distribution of Various Lesions of Gall Bladder (n=150)

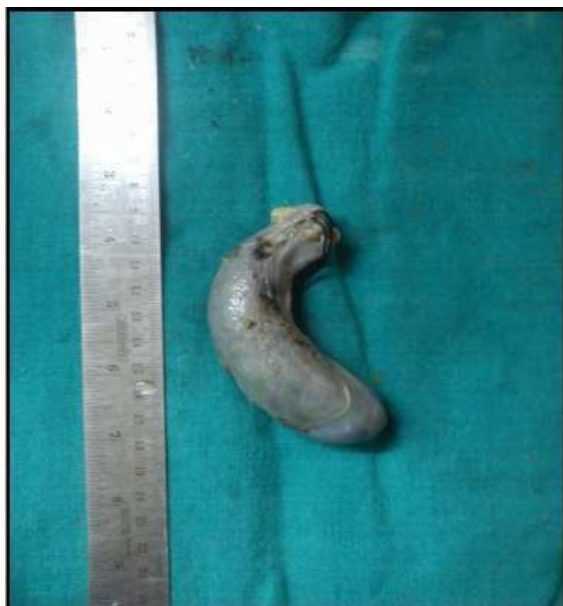Diagnosis	Number of Cases	Percentage
Cholecystitis		
Acute on chronic cholecystitis	3	2%
Chronic Cholecystitis	110	73.34%
Follicular	1	0.67%
Xanthogranulomatous	3	2%
Cholesterolosis	15	10%
Mucocele	1	0.67%
Cholecystitis with hyperplasia		
Adenomatous	5	3.33%
Adenomyomatous	3	2%
Cholecystitis with metaplasia		
Intestinal	5	3.33%
Carcinoma	4	2.66%



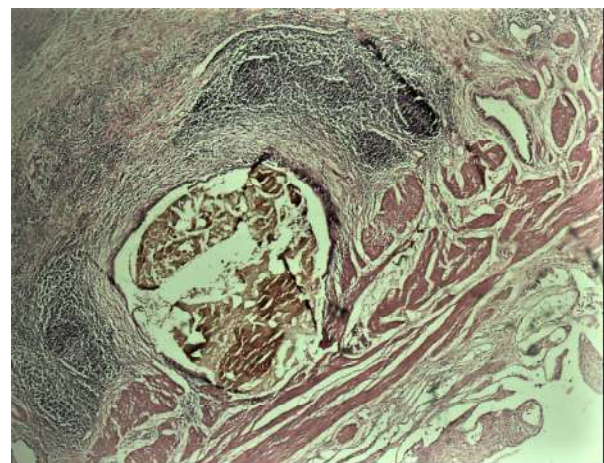
**Fig. 2:** Showing cut section of gallbladder specimen with bile stained mucosa and presence of multiple, multi faceted mixed stones



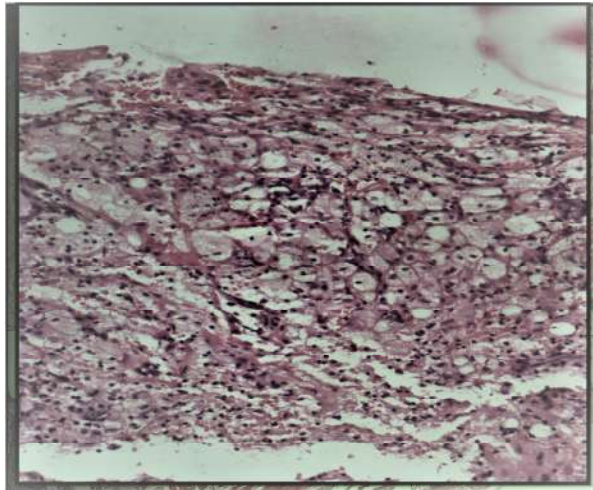
**Fig. 3:** Acute on chronic cholecystitis: Showing ulceration and mild edema with inflammation. (H & E, 200X)



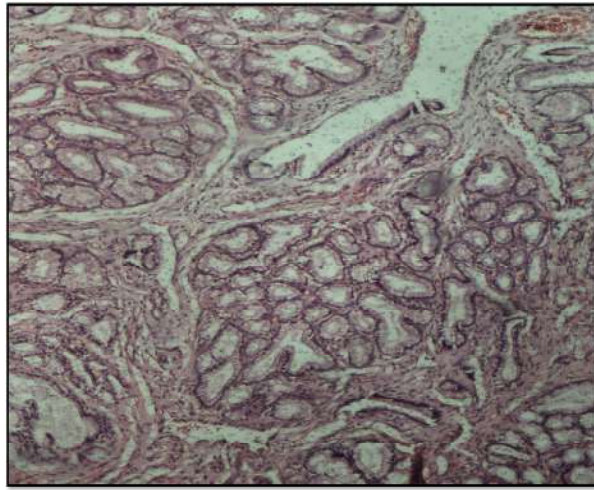
**Fig. 1:** Showing specimen of distended gallbladder.



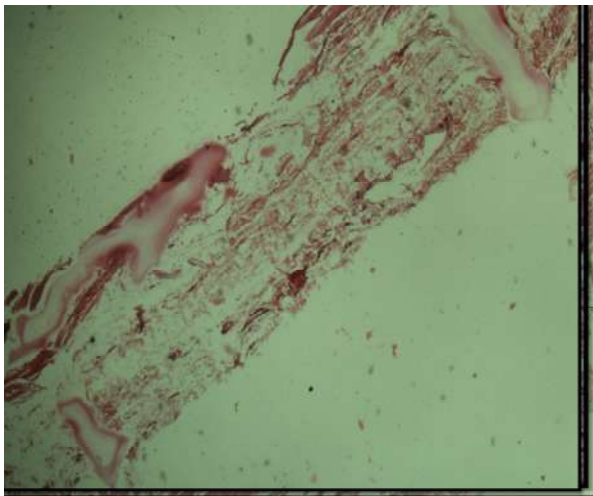
**Fig. 4:** Follicular cholecystitis showing presence of lymphoid follicles in lamina propria layer. (H & E, 400X)



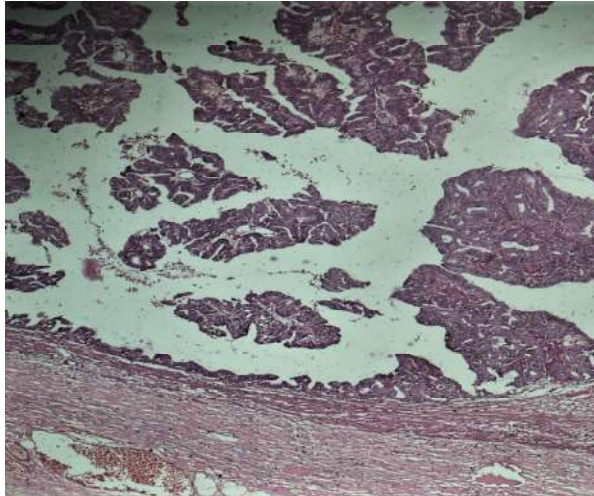
**Fig. 5:** Xanthogranulomatous cholecystitis showing diffuse collection of macrophages (xanthoma cells) gallbladder wall. (H & E, 200X)



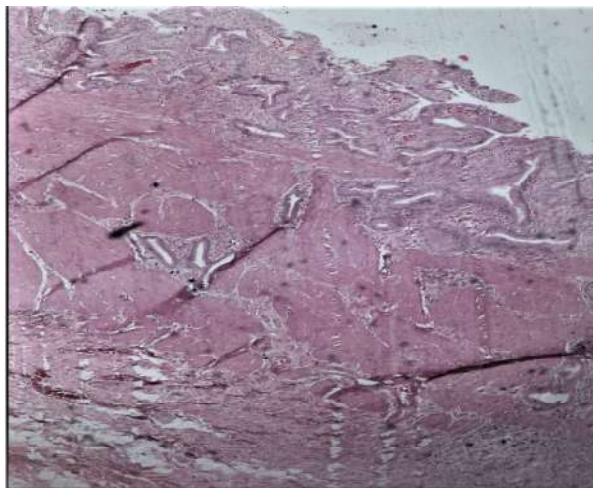
**Fig. 8:** Adenomatous hyperplasia showing diffuse proliferation of glands. (H & E, 100X)



**Fig. 6:** Mucocele showing presence of mucinous material in the gallbladder wall, with ulcerated mucosa. (H & E, 40X)



**Fig. 9:** Well differentiated adenocarcinoma infiltrating in gallbladder wall and composed predominantly of papillary structures lined by cuboidal or columnar epithelial cells. (H & E 40 X)



**Fig. 7:** Adenomyoma showing muscular hypertrophy with focal proliferation of glands. (H & E 400X)

## Discussion

Gall bladder is most common location for malignancy in whole biliary tract. In India incidence among females and males is 2.3 and 1.01 per 100,000 respectively. Number of cases in North India are 10 times more than South India [10]. If we compare risk factors, gallstones seems to be the most important, being reported in 70-98% cases of gallbladder cancer, a far more important than that in age-matched general population [11].

Autopsy findings indicate similar trends. It revealed that 1-4% of patients with cholelithiasis develop cancer compared to less than 0.2% of

those not containing stones [12]. Clinical and pathological data does not conclusively establish any relationship between gall stones and cancer but its facilitative role could be debated.

Cholelithiasis leads to a series of epithelial changes, including hyperplasia, metaplasia and dysplasia. Epithelial hyperplasia was present in 5.33% of cases in our study. Albores - Saavedra *et al.* explained that few cases of hyperplasia transforms into atypical hyperplasia and then they converts into in situ carcinoma, further leading to invasive carcinoma [13]. Metaplasia of the antral and intestinal variety is frequently seen in gallbladders containing stones. But in our study we only came across intestinal metaplasia in 3.33% of cases, while in other studies its incidence was between 50 to 100% [14,15]. It was found that mucous gland hyperplasia and metaplasia frequency increases with age and commonly found after 50 years of age. Many studies concluded that metaplastic epithelium is more vulnerable to malignant transformation than normal epithelium. According to Yamamoto *et al* there may be two histogenetic pathways for gallbladder cancer, one path derived from normal epithelium and the other from metaplastic epithelium [16].

Out of 4 cases of invasive carcinoma, dysplasia was present in the adjacent mucosa in 2 (50%) cases. In Martinez *et al.* study, low-grade dysplasia was present in 40% of cases and high-grade dysplasia was present in 16% of cases with gall stones. According to others studies, the incidence of dysplasia was 2.2% of cholelithiasis specimens but incidence of dysplasia increases exponentially to 42% in gall bladder mucosa which is adjacent to carcinoma [17]. Suggesting that dysplasia and carcinoma are closely related. Wide discrepancy of incidence of dysplasia in various studies may due to different architectural and cytological criteria followed by different pathologists or institutes. Thus, interpretation may vary from pathologist to pathologist.

In our study most common stone was mixed (56.66%) and 3 out of 4 cases of carcinoma also had mixed stones. But this findings statistically insignificant to prove that mixed stones are responsible for carcinoma because most common stone in whole study was mixed stones.

### Conclusion

Presence of stones may lead to different mucosal changes from chronic inflammation to carcinoma.

Therefore histopathological examination of all cholecystectomy specimens with or without cholelithiasis is essential to rule out malignant pathology.

### References

1. Baig SJ, Biswas S, Das S, Basu K and Chattopadhyay G. Histopathological changes in gallbladder mucosa in cholelithiasis: correlation with chemical composition of gallstones. *Trop Gastroenterol.* 2002; 23:25-27.
2. Meyer G, Guizzardi F, Rodighiero S, Manfredi R, Saino S, Sironi C, *et al.* Ion transport across the gallbladder epithelium. *Curr Drug Targets Immune Endocr Metabol Disord.* 2005;5:143-51.
3. Aust S, Obrist P, Jaeger W, Klimpfinger M, Tucek G, Wrba F, *et al.* Thalhammer T Subcellular localization of the ABCG2 transporter in normal and malignant human gallbladder epithelium. *Lab Invest.* 2004; 84:1024-36.
4. Kuver R, Klinkspoor JH, Osborne WR, Lee SP. Mucous granule exocytosis and CFTR expression in gallbladder epithelium. *Glycobiology.* 2000; 10:149-57.
5. Afdhal NH. Cholesterol crystal nucleation: A decade-long search for the missing link in gallbladder pathogenesis. *Hepatology.* 1990;11:669-702.
6. Velanovich VF. Biliary dyskinesia and biliary crystals: a prospective study. *Am Surg.* 1997; 63:69-73.
7. Lange K, Gottschalk M. Gallbladder contractility in early stages of lithogenesis in the lithogenic fed guinea pig. *Z. Gastroenterol.* 1995;33:333-39.
8. Kouroumalis E, Hopwood D, Ross PE, Milne G, Bouchier IA. Gallbladder epithelial acid hydrolases in human cholecystitis. *J Pathol.* 1983;139:179-91.
9. Albores-Saavedra J, Alcantra Vazquez A, Cruz Ortiz H, Herera Goepfer R. The precursor lesions of invasive gallbladder carcinoma. Hyperplasia, atypical hyperplasia and carcinoma in situ. *Cancer* 1980;45:919-27.
10. Dhir V, Mohandas KM. Epidemiology of digestive tract cancers in India. *Indian J Gastroenterol* 1999;18:24-8.
11. Al-Hadeedi SY, Moorhead RI, Leaper DJ, Wong J. Carcinoma of the gallbladder: A diagnostic challenge. *J Coll Surg Edin.* 1991;36:174-7.
12. Silk YN, Douglas HO, Nava HR, Driscoll DL. Carcinoma of the gallbladder. *Ann Surg* 1989;210:751-7.
13. Albores - Saavedra J, Molberg K, Henson DE. Unusual malignant epithelial tumors of the gallbladder. *Semin Diagn Pathol.* 1996;13:326-38.
14. Yamigava H, Tamiyama H. Intestinal metaplasia

- Dysplasia carcinoma sequence of the gallbladder. *Acta Pathol Jpn.* 1986;36:989-97.
15. Martinez-Guzman-e, de-la Rosa-Bayan J. Neoplasma and dysplasia of the gallbladder and their relationship with lithiasis. A case control clinic pathological study. *Rev Gastroenterol Mex.* 1998;63:82-8.
16. Yamamoto YM, Nakajo S, Tahara E. Carcinoma of the gallbladder: The correlation between histogenesis and prognosis. *Virchows Arch Pathol Anat.* 1989;414:83-90.
17. Martinez-Guzman-e, De-la Rosa-Bayan J. Neoplasma and dysplasia of the gallbladder and their relationship with lithiasis. A case control clinic pathological study. *Rev Gastroenterol Mex.* 1998;63:82-8.

